

A Bone-Borne Appliance for Rapid Maxillary Expansion

HEINZ WINSAUER, MD, DDS
JULIA VLACHOJANNIS, MD, DDS, MSc
CLEMENS WINSAUER, CMD
BJÖRN LUDWIG, DMD, MSD
ANDRE WALTER, MD, DDS, MSc

Since the introduction of nonsurgical rapid maxillary expansion (RME) for the treatment of transverse deficiencies in 1860, maxillary expanders have been part of the orthodontist's armamentarium. A survey of German orthodontists revealed that most employed RME in adolescents with transverse maxillary deficiencies requiring an average 5mm of expansion.¹

Although Orthosystem* mini-implants have been used successfully for palatal expansion,^{2,3} this method carries the risk of root injury and the need for surgical implantation and removal of the two titanium cylinders. Other bone-borne expanders, such as the Mommaerts,⁴ Magdeburg,⁵ and Rotterdam distractors,⁶ must be placed under general anesthesia by oral surgeons and have been associated with technical problems.

As an alternative, Wilmes and colleagues introduced the bone- and tooth-borne Hybrid

Hyrax, which is anchored by palatal miniscrews and first-molar bands.⁷ Based on a systematic review of palatal bone height and density,⁸ we were encouraged to develop a strictly bone-borne device, the MICRO ("mini-implant collar-retained orthodontic") expander, as described in this article.

Appliance Fabrication

Four or six Dual-Top** Jet miniscrews (2-2.5mm in diameter, 10-14mm long) are inserted exactly perpendicular to the anterior palate, 3-9mm lateral to the sutura palatina mediana, in an area posterior to a line between the canine and

*Registered trademark of Institut Straumann, Waldenburg, Switzerland; www.straumann.com.

**Trademark of Jeil Medical Corporation, Seoul, Korea; www.jeilmed.co.kr.



Dr. H. Winsauer



Dr. Vlachoianis



Dr. C. Winsauer



Dr. Ludwig



Dr. Walter

Drs. Heinz Winsauer, Vlachoianis, and Clemens Winsauer are in the private practice of orthodontics at Belruptstr. 59, 6900 Bregenz, Austria. Dr. Ludwig is a Contributing Editor of the *Journal of Clinical Orthodontics*; an Instructor, Department of Orthodontics, University of Homburg, Saar, Germany; and in the private practice of orthodontics in Traben-Trarbach, Germany. Dr. Walter is an Associate Professor, Department of Orthodontics, Universitat Internacional de Catalunya, Barcelona, Spain.

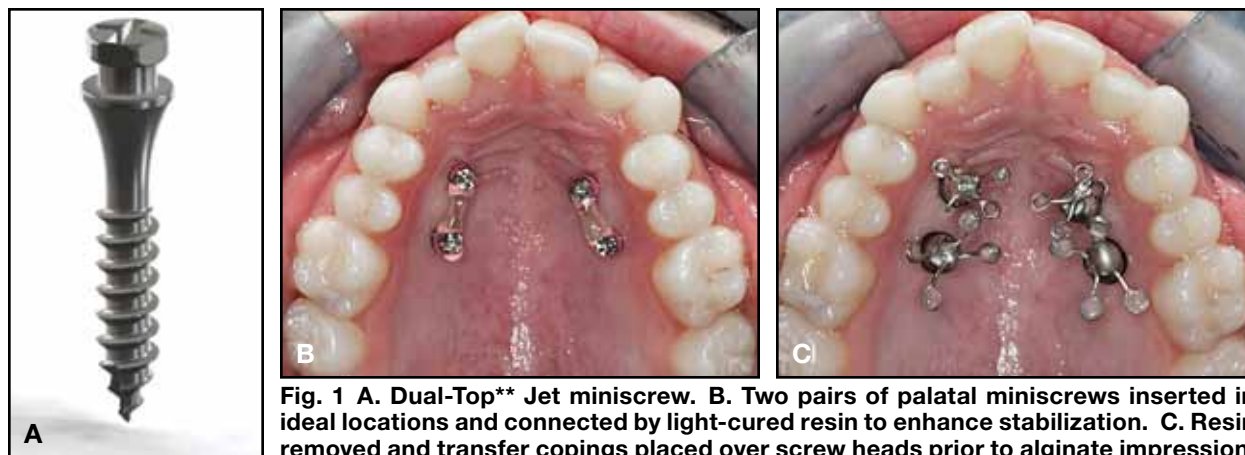


Fig. 1 A. Dual-Top** Jet miniscrew. B. Two pairs of palatal miniscrews inserted in ideal locations and connected by light-cured resin to enhance stabilization. C. Resin removed and transfer copings placed over screw heads prior to alginate impression.

first-premolar contact points and anterior to a line between the second-premolar and first-molar contact points (Fig. 1). Slight variations in location are acceptable, depending on the individual patient anatomy.⁸ The Dual-Top Jet screw features a long upper shank that is unthreaded and polished to lessen gingival irritation; the 7mm threaded portion is shaped differently from that of other Dual-Top screws. The MICRO-4 Hyrax, with four palatal miniscrews, is used for adolescents; the MICRO-6 Hyrax, with six miniscrews, for adults.

The screw heads are coated and the right and left pairs or sets of three are connected using Triad*** light-cured resin (Fig. 1B). This improves patient comfort and, in patients older than 16, ensures adequate secondary stability within a six-to-12-week retention period. Since the bony sutures are generally open in young adolescent patients, the MICRO-4 expander can be placed immediately after the mini-implants are inserted. Before an alginate impression is taken for fabrication of the expander, the Triad resin coating is removed and metallic transfer copings are snapped onto the screw heads (Fig. 1C). When the impression is removed from the mouth, the transfer copings remain in the alginate. The light-cured resin is reapplied after the impression is taken.

In the laboratory, miniscrew analogs are placed in the transfer copings (Fig. 2A), and a plaster cast is poured. Special stainless steel collars† are placed over the screw heads, and the arms

of a Hyrax screw are bent to fit into the collars' circumferential grooves and laser-welded in place (Fig. 2B). Depending on the space available between the miniscrews, either a regular Hyrax screw with four lateral arms (see Case 1) or a special Hyrax screw† with four anterior arms (see Case 2) is used. The miniscrew collars are connected on each side for stability (Fig. 2C).

Before the appliance is fitted in the mouth, the light-cured resin is again removed from the screw heads. Phase II‡ self-curing composite is injected into the miniscrew collars, using an insulin syringe modified for this purpose by removing the needle and shortening and shaping the nozzle to fit the collar (Fig. 2D). Excess composite is expressed through a small outlet hole, so that the collar is completely filled with paste (Fig. 2E). After 90 seconds, the self-curing process starts, providing a stable connection between screw head and collar (Fig. 2F). Stress testing has demonstrated that this connection is so strong that the screw shank will bend before the collar detaches from the screw head (Fig. 2G).

**Trademark of Jeil Medical Corporation, Seoul, Korea; www.jeilmed.co.kr.

***Registered trademark of Dentsply International, York, PA; www.dentsply.com.

†Tiger Dental, Bregenz, Austria; www.tigerdental.com.

‡Registered trademark of Reliance Orthodontic Products, Inc., Itasca, IL; www.relianceorthodontics.com.

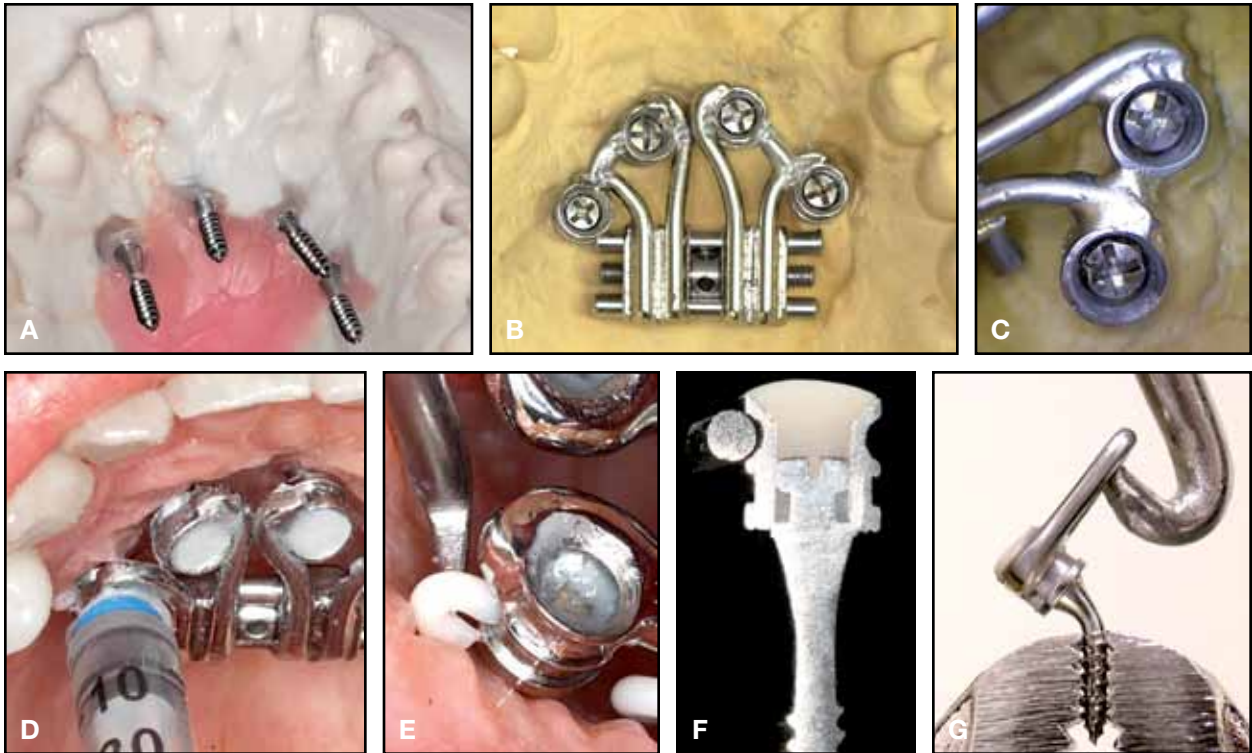


Fig. 2 A. Alginate impression with embedded transfer copings and analog miniscrews in place. B. MICRO-4 Hyrax expander laser-welded to miniscrew collars on plaster cast. C. Collars connected before cementation for added stability. D. Injection of Phase II⁺ self-curing composite into collars around screw heads. E. Excess paste expressed through outlet hole. F. Cutaway view through cemented collar and screw head. G. Applied moments and forces will bend screw shaft before collar detaches.

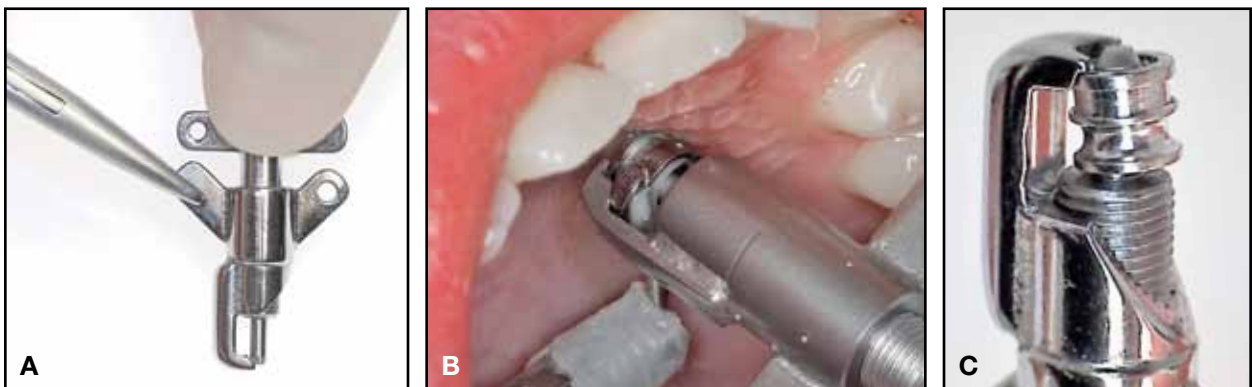


Fig. 3 A. Collar extractor with central bolt and tempered stainless steel finger, securely held in place with needle holder. B. Extractor finger placed in groove under collar and central bolt tightened. C. Extractor with removed collar.

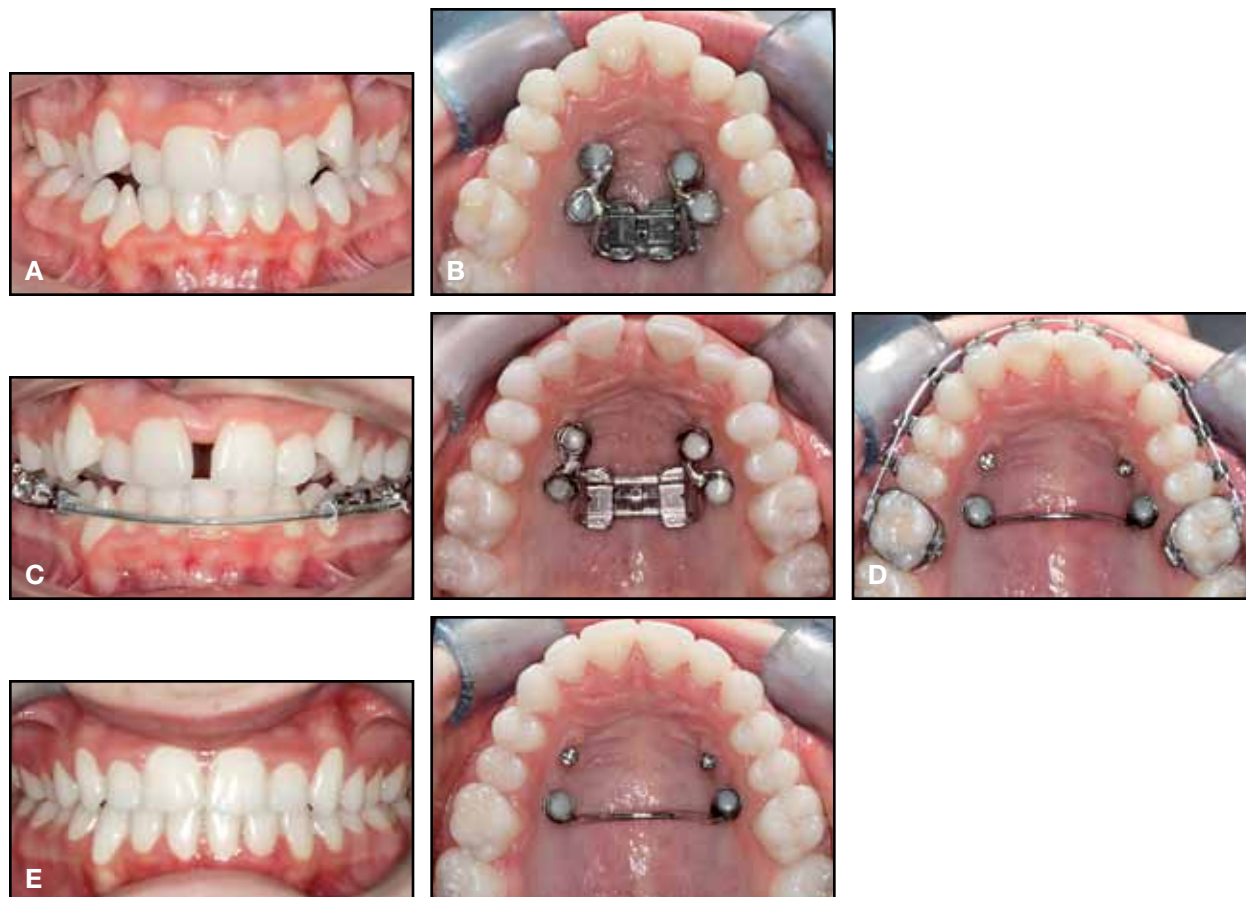


Fig. 4 Case 1. A. 14-year-old female patient with narrow maxilla, broad mandible, and lingually tipped lower posterior teeth before treatment. B. MICRO-4 Hyrax expander with Forestadent^{††} Hyrax screw. C. Expansion after 20 days of activation. D. 12 months later, after six months of expansion maintenance with passive expander and six months with MICRO-TPA bonded to posterior miniscrews. E. Patient after 14 months of treatment.

After removal of the excess composite, the MICRO-4 Hyrax is activated with one or two 90° turns, producing an immediate, pronounced increase in tension. The patient is instructed to activate the expander .3mm or less per day until the desired width is achieved. After expansion is complete, the MICRO-4 Hyrax expander is left in place for about six months of retention. In adult cases, a maintenance phase of 12 months or even longer is advised.

The first step in detachment of the appliance is to remove the composite from inside the collar with a bur until the screw head is visible. A collar

extractor[†] is then used to remove the collar from each screw head (Fig. 3). The extractor's central bolt rests on the screw head as a counter bearing, and a tempered stainless steel finger is placed in the groove under the collar. When the extractor screw is tightened, the finger lifts the collar away from the screw head. The miniscrews can be removed or used for other purposes, including molar distalization with the TopJet distalizer or transverse retention with a collar-bonded transpalatal arch (TPA), as in Case 1.

[†]Tiger Dental, Bregenz, Austria; www.tigerdental.com.

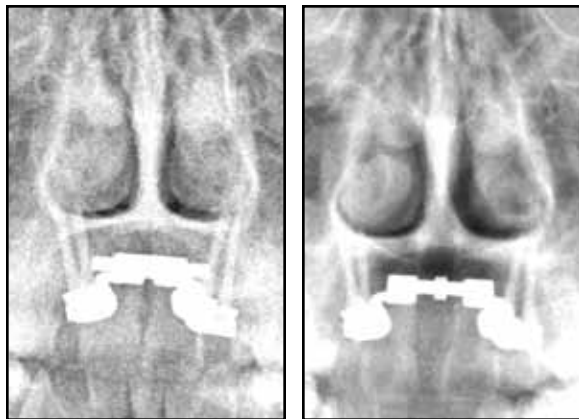


Fig. 5 Case 1. Posteroanterior radiographs of maxilla before and after suture opening show unchanged inclination of miniscrews, dehiscence of midpalatal suture, and significant enlargement of nasal cavity.

The following two cases illustrate the use of MICRO-4 Hyrax expanders in adolescent patients.

Case 1

A 14-year-old female presented with a narrow maxilla, an upper arch-length discrepancy, a broad mandible, and lingually tipped lower posterior teeth (Fig. 4A). A MICRO-4 expander based on a Forestadent^{††} Hyrax expansion screw with four lateral arms was placed (Figs. 1B,C and 4B). After 20 days, 5.8mm of maxillary expansion had been achieved, and brackets were bonded in the lower arch to begin uprighting with a ribbon archwire (Fig. 4C). The deactivated expander remained in place for six months of stabilization; a MICRO-TPA was then bonded to the posterior miniscrews to maintain the palatal width for another six months during final orthodontic movement (Fig. 4D). After a total 14 months of treatment, the upper and lower buccal teeth had been uprighted and the case finished (Fig. 4E).

The desired maxillary width was achieved without any visible migration of the mini-implants (Fig. 5). The posteroanterior radiographs also demonstrated dehiscence of the midpalatal suture and a significant enlargement of the nasal cavity.

Case 2

A 16-year-old female presented with a bilateral posterior crossbite and a midline diastema (Fig. 6A). Although the patient's maxilla was not small, her mandible was extremely large, necessitating a considerable amount of maxillary expansion.

A MICRO-4 expander based on a Hyrax expansion screw[†] with four anterior arms was placed (Fig. 6B). After 25 days, 9mm of expansion had been achieved; the occlusal radiograph showed a bony dehiscence corresponding to the expansion of the Hyrax screw. Because of the large resulting diastema, the central-incisor crowns were built up with mesial composite shoulders (Fig. 6C), using minimal enamel conditioning so that the shoulders could easily be reduced as the diastema closed. The expander was left in place for six months to maintain the expansion during orthodontic treatment with fixed appliances.

Two months after removal of the expander and miniscrews, brackets were debonded (Fig. 6D). Total treatment time was 10 months.

Discussion

Rapid palatal expansion is easily accomplished in growing patients and is also possible in young adults.⁹ In skeletally mature patients, however, the resistance to mechanical maxillary expansion increases. Ulcerations, failure to expand, pain, and swelling were reported by more than half of the patients in one study.¹⁰

In a survey of German orthodontists, most clinicians noted buccal tipping of the anchorage teeth after tooth-borne RME; pain, relapse, mobility of the anchorage teeth, and nosebleeding were also observed.¹ In contrast, the bone-borne anchorage of MICRO expanders avoids unwanted dental effects such as root resorption and tipping of the buccal teeth. Placement and removal of the miniscrews require neither surgical procedures nor general anesthesia and are feasible for orthodontists to do themselves. The time needed for each step of the procedure—miniscrew placement,

^{††}Forestadent, Pforzheim, Germany; www.forestadent.com.

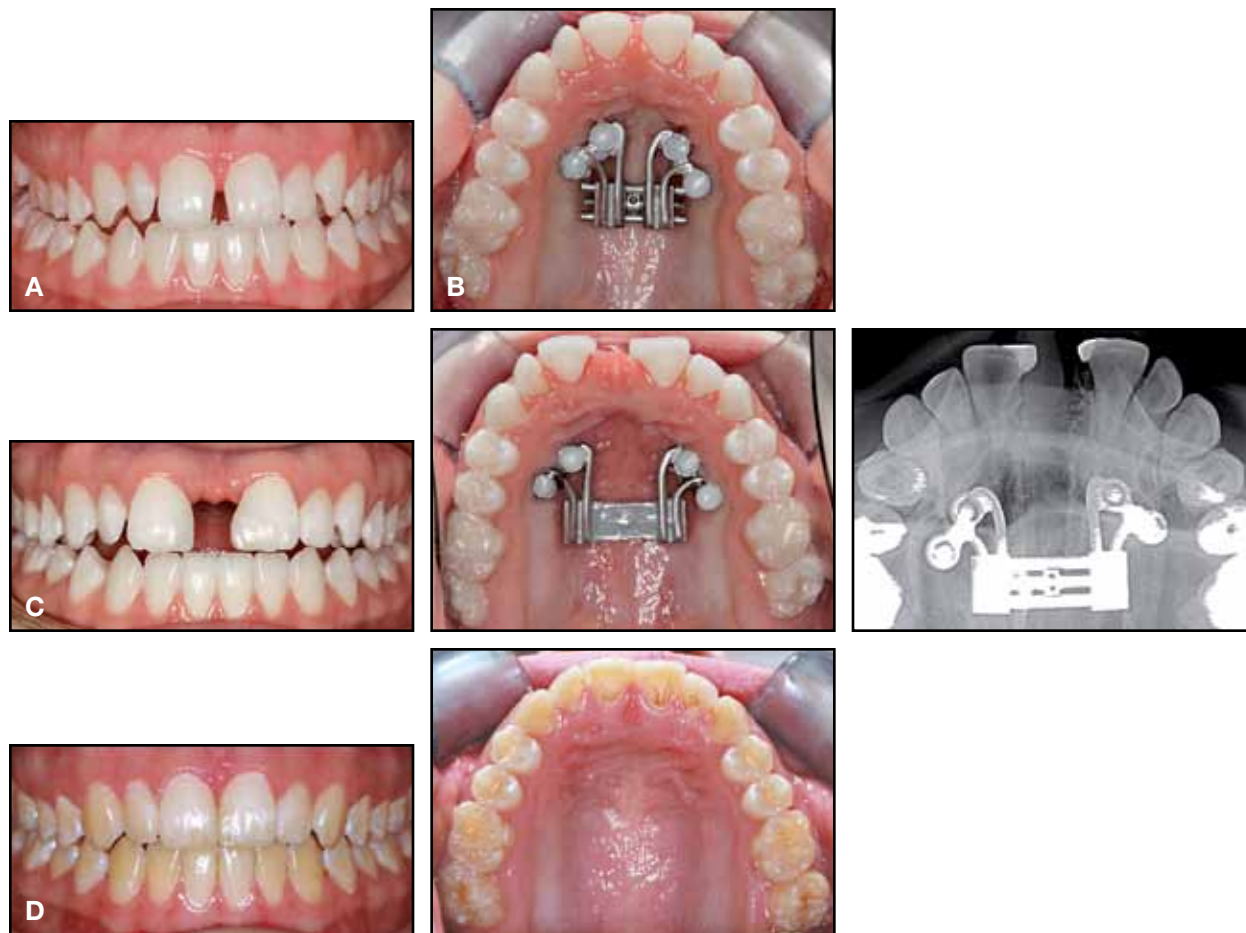


Fig. 6 Case 2. A. 16-year-old female patient with midline diastema, normal maxilla, and extremely large mandible before treatment. **B.** MICRO-4 Hyrax expander based on Hyrax screw† with four anterior arms. **C.** Expansion after 25 days of activation; composite shoulders added to mesial surfaces of central incisors for esthetics during subsequent fixed-appliance treatment. **D.** Patient after 10 months of treatment, including six months of orthodontics.

alginate impression with transfer copings, appliance insertion, and appliance removal—is usually less than 10 minutes. The MICRO-4 expander also allows simultaneous fixed-appliance treatment during the expansion and retention phase, and it appeals to patients from an esthetic point of view.

A MICRO-4 expander can be used in late-mixed-dentition patients with missing teeth. We have successfully employed the MICRO-6 Hyrax expander (Fig. 7) to widen the palatal suture in adults as old as 40. Of course, if expansion does not progress in an adult, surgically assisted RME

may become necessary. Although the extent of surgery should be based on the individual patient's areas of resistance, there is no conclusive recommendation for surgical cuts¹¹; we have seen good results from a minimally invasive bilateral corticotomy and pterygoid maxillary disjunction. The MICRO expander can be left in place during surgery. Still, Kurt and colleagues showed that non-surgical orthodontic maxillary expansion (patients with a mean age of 15.5) was as stable as surgi-

†Tiger Dental, Bregenz, Austria; www.tigerdental.com.

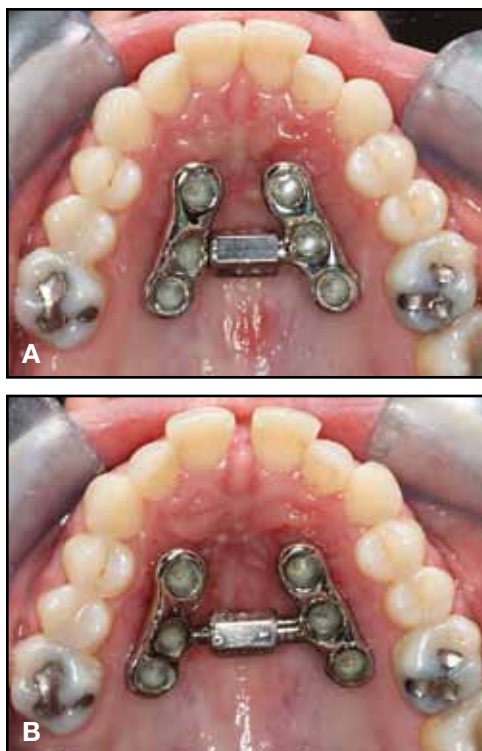


Fig. 7 A. 31-year-old female patient with MICRO-6 Hyrax expander in place. **B.** Expansion completed 18 days later.

cally assisted RME (mean age of 19.0) three years after treatment, with some amount of post-retention relapse compared to the control group (mean age of 15.2).¹²

Conclusion

Direct fixation of Hyrax expanders to the palatal bone is an alternative to tooth-borne appliances that may allow palatal expansion in more mature patients. The minimally invasive four- or six-point MICRO Hyrax expander has successfully opened the midpalatal suture in 31 of our

cases and has proven sufficiently stable while preventing asymmetrical movement of the maxilla. Unwanted side effects, if any, are restricted to palatal strain. Other advantages include the capability of simultaneous orthodontic tooth movement, ease of insertion and removal, esthetic appearance, and patient comfort.

REFERENCES

1. Korbmacher, H.; Huck, L.; Merkle, T.; and Kahl-Nieke, B.: Clinical profile of rapid maxillary expansion—outcome of a national inquiry, *J. Orofac. Orthop.* 66:455-468, 2005.
2. Harzer, W.; Schneider, M.; and Gedrange, T.: Rapid maxillary expansion with palatal anchorage of the hyrax expansion screw—pilot study with case presentation, *J. Orofac. Orthop.* 65:419-424, 2004.
3. Hansen, L.; Tausche, E.; Hietschold, V.; Hotan, T.; Lagravère, M.; and Harzer, W.: Skeletally-anchored rapid maxillary expansion using the Dresden Distractor, *J. Orofac. Orthop.* 68:148-158, 2007.
4. Mommaerts, M.Y.: Transpalatal distraction as a method of maxillary expansion, *Br. J. Oral Maxillofac. Surg.* 37:268-272, 1999.
5. Gerlach, K.L. and Zahl, C.: Transversal palatal expansion using a palatal distractor, *J. Orofac. Orthop.* 64:443-449, 2003.
6. Koudstaal, M.J.; van der Wal, K.G.; Wolvius, E.B.; and Schulten, A.J.: The Rotterdam Palatal Distractor: Introduction of the new bone-borne device and report of the pilot study, *Int. J. Oral Maxillofac. Surg.* 35:31-35, 2006.
7. Wilmes, B.; Nienkemper, M.; and Drescher, D.: Application and effectiveness of a mini-implant- and tooth-borne rapid palatal expansion device: The Hybrid Hyrax, *World J. Orthod.* 11:323-330, 2010.
8. Winsauer, H.; Vlachoianis, C.; Bumann, A.; Vlachoianis, J.; and Chrubasik, S.: Paramedian vertical palatal bone height for mini-implant insertion: A systematic review, *Eur. J. Orthod.*, in press.
9. Stuart, D.A. and Wiltshire, W.A.: Rapid palatal expansion in the young adult: Time for a paradigm shift? *J. Can. Dent. Assoc.* 69:374-377, 2003.
10. Capelozza Filho, L.; Cardoso Neto, J.; da Silva Filho, O.G.; and Ursi, W.J.: Non-surgically assisted rapid maxillary expansion in adults, *Int. J. Adult Orthod. Orthog. Surg.* 11:57-66, 1996.
11. Suri, L. and Taneja, P.: Surgically assisted rapid palatal expansion: A literature review, *Am. J. Orthod.* 133:290-302, 2008.
12. Kurt, G.; Altug-Ataç, A.T.; Ataç, M.S.; and Karasu, H.A.: Stability of surgically assisted rapid maxillary expansion and orthopedic maxillary expansion after 3 years' follow-up, *Angle Orthod.* 80:425-431, 2010.